



PATIENT

Nemo Randev

SPECIES

Feline

BREED

DLH

SEX

Male Neutered

AGE

7 years

WEIGHT

16.3lbs

INTERPRETED BY

Maggie Machen Lamy,
DVM, DACVIM
(Cardiology)

IMAGING PERFORMED BY

Dr. Belan, DVM

HOSPITAL NAME

Properties Animal
Clinic

REFERRING VET

Dr. Costa

INVOICE

25546

DATE

7/26/22

PRESENTING CLINICAL SIGNS

History: Heart murmur diagnosed 3 years ago: grade 2/6 then now grade 3/6 now. Nonclinical. No medications.

ECHOCARDIOGRAM FINDINGS

2D, m-mode, color flow and doppler imaging is available. The left ventricular wall is irregular with a focal septal thickening and a borderline free wall dimension. There is a diffusely hyperechoic endocardium consistent with fibrosis. The papillary muscles are mildly hypertrophied and hyperechoic. The endocardium also appears normal. The left atrium is normal in size. The right atrium is normal in size. The right ventricle appears normal. The mitral valve is normal in structure and mobility with trace MR. No TR. Blood flow through the RVOT is normal. The blood flow through the LVOT is normal on doppler; however, an intermittent LVOTO is suspected on ancillary imaging. No pleural or pericardial effusion seen. No obvious cardiac tumors.

CARDIAC CHART

| FELINE CARDIAC PARAMETERS | BODY WEIGHT (kg) | HR (BPM) | IVSd (cm) (Moise, Pipers) | LVIDd (cm) (Moise, Pipers) | LWVd (cm) (Moise, Pipers) | FS (%) | EF (%) |
|---------------------------|------------------|---------------------------------|--|----------------------------|---------------------------|----------------|-------------|
| NORMAL PARAMETER | ----- | 150-240 | 0.35-0.55 | <2 (mean 1.5) | 3.5-0.55 | 35-67 | 80-100 |
| PATIENT | 7.4 | 230 | 0.68 | 1.2 | 0.54 | 50 | 85 |
| FELINE CARDIAC PARAMETERS | LA/AO (Boon) | LA/AO HEART BASE (Swe) (Abbott) | LA 2D short axis Base view (cm) (Abbott) | | LVOT VEL (m/s) | RVOT VEL (m/s) | E max (m/s) |
| NORMAL | <1.5 | <1.3 | <1.2 | | <1.6 | <1.3 | <0.9 |
| PATIENT | 1.5 | 1.3 | 1.2 | | 1.4 | 1.44 | NM |

**Note: All measurements based upon multi-modal images and methods. An average value is reported.*
Adapted from June Boon, Veterinary Echocardiography, 1998
Abbott J & MacLean H JVIM 2006;20: 111-119, Moise et al. Am J Vet Res 47:1476, 1986. Pipers et al. Am J Vet Res 40:882, 1979.

INTERPRETATION OF THE FINDINGS & FURTHER RECOMMENDATIONS

The primary abnormality identified is focal LV hypertrophy in addition to LV remodeling, which may be indicative of early hypertrophic disease or may simply represent a normal variant. The LA is normal which would indicate clinical stability. Serial echocardiography will be necessary to determine progression and clinical significance. Additionally, the murmur is due to a mild LVOT obstruction with secondary MR, which appears intermittent and does not warrant therapy. No additional issues are identified.

Anesthetic risk is considered mild, however judicious IV fluid rates are advised to avoid fluid overload. Additionally, drugs that stimulate heart rate should be avoided unless clinically necessary (glycopyrrolate, atropine). Avoid vasodilators as this may worsen the obstruction. A reasonable protocol includes opioid/benzodiazepine premedication, propofol induction, isoflurane maintenance. Additionally, steroids should be used with caution on older cats, as even a 'normal' geriatric heart can develop evidence of intolerance and fluid retention.



PATIENT

Nemo Randev

Monitor for any development of clinical signs, including labored breathing or signs of a blood clot (paralysis, neurologic change).

SPECIES

Feline

PLAN

BP and T4 should be monitored every 6 months.

BREED

DLH

A recheck echocardiogram is recommended in 6-12 months to screen for any evidence of progression.

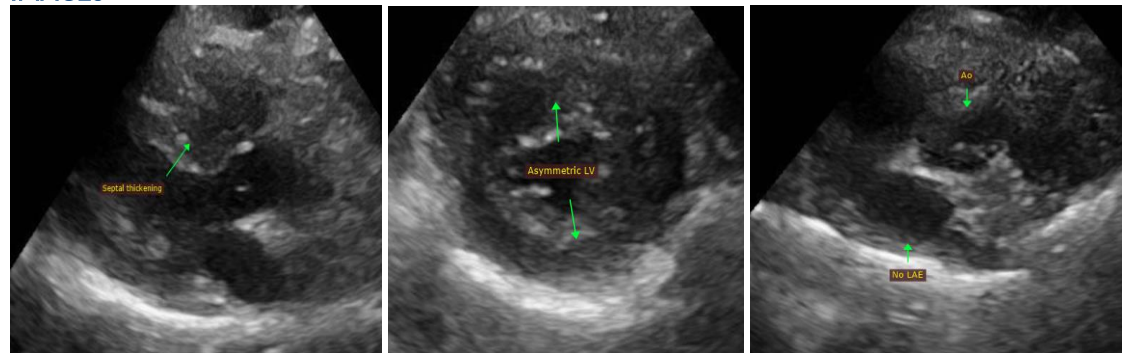
SEX

Male Neutered

IMAGES

AGE

7 years



WEIGHT

16.3lbs

The information and recommendations provided are based on the images presented by the referring veterinarian. No evaluation can be communicated regarding pathology that was not visible in the image/video clips provided.

INTERPRETED BY

Maggie Machen Lamy,
DVM, DACVIM
(Cardiology)

Thank you for this referral. This report was generated using transcription software, and minor dictation errors may be present. If the clinical or image interpretation does not parallel your findings or if I can be of any further assistance, please contact me.

IMAGING PERFORMED BY

Dr. Belan, DVM

Maggie Machen Lamy, DVM
Diplomate of the American College of Veterinary Internal Medicine (Cardiology)
info@sonopath.com

HOSPITAL NAME

Properties Animal
Clinic

REFERRING VET

Dr. Costa

INVOICE

25546

DATE

7/26/22